

CHAPTER 12. OCCLUSION

Section 1. Temporomandibular Disorders

DEFINITIONS

Temporomandibular Joint (TMJ): The connecting sliding hinge mechanism between the mandible and the temporal bone (base of the skull).

Temporomandibular Disorders (TMD): A group of disorders including myofascial pain-dysfunction syndrome (MPD), disk (meniscal) displacement with or without reduction (internal derangement), degenerative joint disease (osteoarthritis), rheumatoid arthritis, and other disorders of systemic origin, facial growth disharmonies, traumatic injuries, and neoplasms.

Internal Derangement: An abnormal relationship of the articular disk to the mandibular condyle, fossa, and/or articular eminence.

Meniscal Displacement with Reduction: The condition wherein the articular disk is located anterior or antero-medial to the condylar head when the jaw is closed. When the jaw is open the disk assumes the normal relationship to the condylar head and articular eminence.

Meniscal Displacement without Reduction: The condition wherein the articular disk is always located anterior or antero-medial to the condylar head regardless of whether the jaw is open or closed.

Myofascial Pain Dysfunction Syndrome (MPD): A group of symptoms including pain and dysfunction involving the muscles of mastication and upper body posture. Considered to be a psychophysiological disorder.

BASIC ANATOMY

The human TMJ is functionally defined as a ginglymoarthrodial (hinge-glide) articulation. A brief synopsis of the joint's basic anatomy follows. The condyle, glenoid fossa, and articular eminence of the temporal bone comprise the bony boundaries of the TMJ. The condyle is elliptical in shape with its mediolateral diameter being greater than its anteroposterior diameter. It is oriented in the fossa with slight medial rotation. The joint is divided into upper and lower compartments by the disk which attaches to the medial and lateral aspect of the condyle. The capsule of the TMJ consists of the strong lateral temporomandibular ligament and 2 weaker medial ligaments. The sphenomandibular ligament attaches to the lingula on the medial aspect of the mandible and the stylomandibular ligament attaches to the posterior border of the ramus (Figure 1).

The joint is innervated by the auriculotemporal nerve and masseteric branches of the trigeminal nerve (V.3). The

blood supply derives from the superficial temporal, middle meningeal, and other associated branches of the internal maxillary artery.

Articular Disk (Meniscus)

The articular disk (meniscus) of the TMJ is a dense, pear-shaped fibrous structure with an inner concave and outer convex surface composed of 4 zones (Figure 2). These zones consist of a moderately thick anterior band, a thin narrow intermediate band, a posterior band which is the thickest area of the disk, and a retrodiskal zone (bilaminar zone) (Rees, 1954). The condyle articulates on the intermediate band.

The central (intermediate) area of the articular disk is avascular. The posterior attachment of the disk, sometimes referred to as the retrodiskal pad, contains numerous large vascular spaces and elastic tissue. The disk appears to have limited capacity for repair and the pathologic changes are usually degenerative (Blackwood, 1969).

Medially and laterally, the articular disk blends with the capsule (which surrounds the disk) and attaches to the condyle. Anteriorly, it attaches to the articular eminence, condyle, and superior head of the lateral pterygoid. Posteriorly, there are firm retrodiskal tissue attachments to the glenoid

Figure 1. Basic anatomy (articulation and capsule)

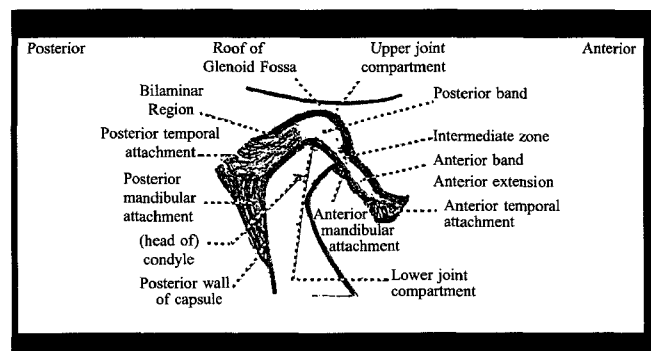
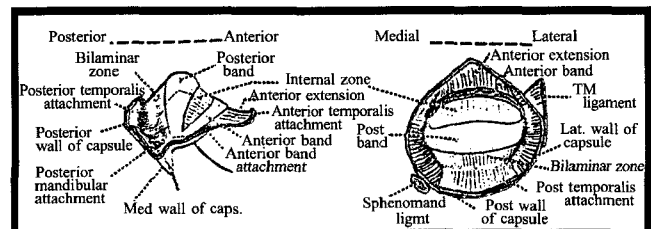


Figure 2. Articular disk (meniscus)



Post = posterior; Ant = anterior

fossa, squamo-tympanic suture, and condyle. Anteriorly, the capsule is reinforced by the temporomandibular ligament, a dense, collagenous ligament without elastic fibers, which functions to maintain contact between articular surfaces and limit extreme movement. No attachment is observed medially.

Mandibular Condyle Histology

There are 3 distinct cell zones in the cartilage of the mandibular condyle during growth: articular zone, proliferative zone, and hypertrophic zone. The proliferative and hypertrophic zones manifest cartilage replacement by mineralized bone, similar to other growing bones. The surface of the articular zone is renewed independent of the proliferative zone, and this difference is reflected in the response of this zone to some of the pathologic processes occurring in this area. With age, the articular zone becomes increasingly fibrous, the proliferative zone is reduced to a narrow band of cells, and the hypertrophic zone is replaced by fibrocartilage (Blackwood, 1969).

Articular Remodeling

Joint remodeling may be progressive, regressive, and peripheral. Progressive and peripheral remodeling constitutes the addition of tissue to the joint surfaces. Peripheral remodeling occurs primarily at the edges of the articular surfaces and occasionally involves the periosteum. Progressive and peripheral remodeling accompanies cellular activity in the proliferative zone, resulting in new cartilage formation and increasing vertical dimension. Regressive remodeling results from osteoclastic resorption of the subarticular bone and replacement with new cartilage and bone, lowering the vertical dimension. During remodeling, the articular surfaces of the joint remain intact and play a relatively passive role by adapting to the changes taking place in the tissues beneath (Blackwood, 1969).

PHYSIOLOGY

There is an average maximum forward movement of 8 mm between the condyle and meniscus, and an average maximum forward movement of 7 mm between the meniscus and temporal bone. As the condyle moves forward, the meniscus is displaced downward and forward, with forward movement due to pull of the lateral pterygoid muscle and attachments to the condyle. During movement, the condyle actually rotates on the disk. The disk is allowed to move forward 7 to 10 mm due to fibro-elastic connective tissue in the posterior attachment which "recoils" on closing (Rees, 1954). Movement between the lower joint structures is rotational while translation occurs between the structures of the upper joint (Okeson, 1991).

CLASSIFICATION OF TMJ DISORDERS

In 1934, Costen associated a number of symptoms, including a variety of ear and sinus problems (impaired hearing; stuffiness; tinnitus; dizziness; headache burning sensation of

throat, tongue, and side of nose) with a dysfunction of the TMJ. Laskin (1969) noted that it took almost 20 years to clarify many of the inaccuracies of this theory which slowly developed into what was termed the "TMJ syndrome." This description eliminated many unrelated symptoms, but still grouped patients with pains of undetermined origin under the same diagnosis. In 1955, Schwartz identified a more definitive subgroup of patients who presented with painful, limited mandibular movement. He attributed this to spasms of the musculature and termed it "temporomandibular joint pain-dysfunction syndrome." Laskin indicated that Schwartz's studies greatly influenced the thinking in this area, resulting in the first major shift away from the narrow mechanical concept of occlusal etiology. Treatment principles included reduction of stress, pain and spasm, therapeutic exercise, and possible judicious occlusal alteration.

In 1983, the American Dental Association convened a special conference of TMJ experts to establish guidelines regarding the examination, diagnosis, and management of temporomandibular disorders (TMD). It was this committee's opinion that temporomandibular disorders should discontinue such terms as "temporomandibular joint dysfunction" and use descriptive terminology. The group agreed that TMD could be classified under three broad headings: those occurring primarily in the muscles of mastication, the TMJ, or related areas mimicking temporomandibular disorders (Griffiths, 1983).

In 1987 and 1989, ADA-sponsored workshops on TMD discussed controversial issues, including TMD classifications. At the 1989 conference (McNeil et al., 1990), TMD was defined as a cluster of related disorders of the masticatory system with common features such as pain, headaches, earaches, joint sounds, and limited mandibular motion. The workshop seemed to approve a classification established by the International Headache Society and the American Academy of Craniomandibular Disorders. The major headings included TMD (disk displacement with and without reduction, hypermobility, dislocation, synovitis, capsulitis, osteoarthritis, osteoarthrosis, and ankylosis) and craniofacial muscle disorders. Currently, however, the masticatory muscle disorders (myofascial pain, myositis, spasm, reflex splinting, hypertrophy, etc.) usually fall under the heading of TMD as well.

INTRINSIC TMJ-ASSOCIATED DISORDERS

An important aspect of diagnosis of TMD includes differentiating disorders originating from intracapsular sources (internal derangements) from those of extracapsular sources (i.e., muscles). Internal derangements or disk-interference disorders, as classified by Okeson in 1991, include: disk displacement or dislocation with reduction; disk dislocation without reduction; adhesions; and alterations in form.

Stockstill and Mohl (1991) reviewed evaluation of TMJ sounds including diagnostic analysis and clinical implications. Joint sounds are often caused by internal derangements but also may be present in "normal" joints as well

as other conditions such as TMJ laxity or condylar movement beyond the eminence. Clicking is the most common joint sound and is caused by the posterior movement of an anteriorly positioned disk or the passage of the condyle against the posterior aspect of the disk during reduction of the disk during jaw opening. Reciprocal clicking produces a similar sound near maximum intercuspation when the disk recoils anteriorly. The authors note that these 2 clicks do not occur at the same jaw position. Crepitus is a grating sound caused by rubbing of irregular articular surfaces or dry synovial surfaces of the joint often associated with degenerative joint disease. The variability in joint sounds and the lack of characterization of sounds for particular disorders limit the importance of TMJ noises unless other signs and/or symptoms of TMD are present.

In 1972, Farrar discussed the diagnosis and treatment of anterior dislocation of the disk indicating that 5% of the patients with TMJ complaints manifest anterior dysfunction. Clinically, there was limitation of opening (24 to 32 mm) with deviation toward the affected side. He stated pain was variable and not necessary for diagnosis. Loss of posterior tooth support on the affected side was a common finding. He felt transcranial radiographs were beneficial in assessing condylar position and joint spaces and thus useful in diagnosis. The 1983 President's Committee concluded such imaging for assessing internal derangements was not reliable and should not be routine (Griffiths, 1983). McNeil et al. (1990) suggest that TMJ imaging is only indicated if a recent or progressive pathological joint condition exists and is not indicated for joint sounds in the absence of other TMD signs and symptoms. Interpretation of TMJ imaging remains a problem. Although technological advances allow imaging using tomography, computed tomography, and magnetic resonance imaging, none of these techniques can predictably differentiate between adaptation and pathologic changes. Prior to the expense and radiation of most imaging techniques, a high probability should exist that the findings of the examination will aid significantly in diagnosis and treatment selection (Dixon, 1991). Farrar's treatment recommendations included manual jaw manipulation to reduce recent disk displacement. If the displacement was painful or had existed for days or weeks, a flat, hard, acrylic bite plane was worn for a few days and then an anterior repositioning splint to move the mandible forward until the disk returned to its normal position (recapturing the disk). This was followed by occlusal equilibration or reconstruction in 4 to 6 weeks.

Anterior repositioning appliances are still being used, although not without controversy. Only 25 to 36% of the patients had long-term reductions of pain and dysfunction (i.e., clicking). Posterior open bites were found to be a problem and occlusal equilibration or rehabilitation was costly, time consuming, and difficult. "Stepping back" the mandible to the original occlusal position to avoid these procedures often proved effective in recapturing the disk. For these reasons,

anterior repositioning appliances should be used with discretion and only if initial treatment with a stabilization appliance (splint) proves unsuccessful (Okeson, 1991).

DISORDERS ASSOCIATED WITH THE MUSCLES OF MASTICATION

In 1969, Laskin stated that the diagnosis of pain dysfunction syndrome is based on 6 signs or symptoms: 1) pain of unilateral origin; 2) muscle tenderness; 3) TMJ clicking or popping; 4) limited jaw function; 5) lack of tenderness in the TMJ when palpated via the external auditory meatus; and 6) absence of organic changes in the TMJ. Guralnick et al. (1978) also listed these symptoms, considering the first 4 as "cardinal signs" of myofascial pain dysfunction (MPD). DeBoever (1980) included ear symptoms, noting their presence in 25 to 37% of the patients, with jaw deviation to the affected side upon opening. The controversy over the importance of occlusion versus the impact of psychosocial stress persists; however, most authorities have discounted the role of occlusal discrepancies. In 1976, Rugh and Solberg supported a psychological component to TMJ pain and dysfunction, but studies were unable to correlate TMD with 1 specific personality trait. There is relatively strong evidence, however, that MPD patients exhibit more emotional anxiety than the average population. Grzesiak (1991) speculated that a unique psychological profile may predispose for MPD, citing a study in which 62% of TMD patients sought care after a significant life event caused a stress response that aggravated a physical condition. Increased masticatory muscle activity, tension, and pain have been related to periods of subjective stress.

BRUXISM

Bruxism is defined as the clenching or grinding of the dentition during non-functional movements of the masticatory system. During sleep, it is termed nocturnal bruxism and during waking hours is called diurnal parafunction. Diurnal parafunction also includes oral habits such as nail biting, finger sucking, tongue thrusting, and chewing on various objects. Most individuals demonstrate signs of bruxism but only 5 to 20% are aware of their parafunctional activity. Simply relying on the patient's history may not be sufficient for diagnosis of nocturnal bruxism. The occlusal wear pattern in a bruxer will result in facets that align while wear facets associated with mastication do not. Nocturnal bruxism has been related to periods of daytime emotional and physical stress and is currently, considered a stress-related sleep disorder. Evidence indicates there is no direct relationship with occlusal interferences, although the etiology is probably multi-factorial and occlusion could play a minor role in certain cases (Attanasio, 1991). Tooth wear, fractured cusps, injury to the periodontium with hypermobility of teeth, hypercementosis, and pulpitis may result from bruxism. Painful masticatory musculature with limitation in mandibular motion is common as is hypertrophy of

the masseters and muscle tension headache pain. Initial therapy should rely on reversible procedures including interocclusal appliances, stress management, physical therapy, pharmacological muscle relaxants, and/or occlusal adjustment (Attanasio, 1991).

CONSERVATIVE TREATMENT FOR TMD

Treatment for TMD should start conservatively, be reversible, and proceed based on need. Early treatment may include patient education and counseling, habit management, physical therapy, bio-feedback, bite-splint appliances, short-term analgesics, and/or muscle relaxants. The diagnosis and etiology will be the determining factor of therapeutic choice. The influence of placebo effect should be noted when treating TMD patients (McNeil et al., 1990).

Greene and Laskin (1983) compared the initial and long-term results of conservative, reversible therapy to 10 previously published papers, regarding irreversible procedures. Patients (175) treated for MPD were interviewed by phone, 1 to 11 years (5-year mean) following completion of treatment. Treatment modalities were variable (oral appliance, biofeedback, psychological counseling, medication, transcutaneous nerve stimulation, placebo), but all were reversible and required some degree of patient cooperation and participation. Immediately following treatment, 74% had been greatly improved, 25% had minor or no improvement, and 1% worsened. Subsequently, 42 patients had sought further treatment. Of this group, 43% reported no additional improvement. However, this group reported gradual improvement after discontinuing therapy. When phoned, 90% of the patients were doing well (53% asymptomatic, 37% minor symptoms), 8% were no better than before treatment, and 2% were worse. In general, patients expressed satisfaction. Two major conclusions resulted from this study. First, those who initially responded well to conservative treatment continued to do well for an extended period of time (whether they received real or placebo treatment). Second, more than half the patients who initially failed to respond to treatment eventually improved. The success rate of this study is similar to previously reported long-term studies. This demonstrates general effectiveness of MPD treatment with no single treatment modality required for success. The authors concluded that irreversible treatments are not necessary for success and are inappropriate.

Clark (1984) reviewed the 5 splint designs including: 1) soft resilient appliances; 2) anterior bite plane hard acrylic splints; 3) full coverage hard acrylic appliances; 4) dynamic exercise or spring-loaded appliances to place opening traction forces on the TMJ of patients with ankylosis, fibrosis and adhesions; and 5) repositioning splints. The author also identified and explained 5 splint theories: 1) occlusal disengagement; 2) restored occlusal vertical dimensions; 3) maxillomandibular realignment; 4) TMJ repositioning; and 5) cognitive awareness. No conclusive and controlled testing of these theories has been accomplished.

Baragona and Cohen (1991) presented a concept of long-term orthopedic appliance therapy. One form of therapy uses a maxillary splint at night and a mandibular splint during the day. Gradual withdrawal of the splint is begun after 1 to 3 asymptomatic months. If patients cannot function without some form of craniomandibular stabilization, if there is a return of painful symptomatology, or if the patient is not a candidate for more aggressive, irreversible treatment, splint therapy may continue indefinitely.

SURGICAL THERAPY

According to Hoffman et al. (1991), approximately 1 to 3% of the population requires or seeks surgical treatment for dysfunctional TMD. Basic indications for arthroscopic surgery include internal joint derangements, condylar hypermobility secondary to intra-articular disorders, foreign bodies, degenerative disease, disk perforation, or radiographic evidence of intra-articular diseases. Treatment includes lysing of adhesions, stretching the fibrotic lateral capsule, and releasing fibrotic attachments of the capsule to the lateral eminence. The joint is lavaged and inspected for mobility. Eminoplasty and plasty of the disk may be accomplished. Physical therapy should commence within 48 hours of arthroscopy. More specific indications for open arthroplasty include osteophytes on the condyle or fossa, ankylosis, implant failure, or cranial perforation. Disk removal may be necessary with or without replacement with alloplastic materials, cartilage grafts, dermis grafts, or temporal fascia. The authors suggest that clinical success in treating joint derangements does not depend on repositioning the disk, but rather, mobilization of joint tissues and removing fibrous tissue to improve disk mobility.

SYSTEMIC PROBLEMS AND CONDITIONS WHICH MIMIC TMD

TMD is responsible for most orofacial pain (Fricton, 1991), but the differential diagnosis of chronic orofacial pain includes a wide variety of other disorders. Chronic pain is pain of 6 months' duration, is not self-limiting, serves no biologic purpose, is often therapeutically non-responsive, and is frequently intensified by psychologic factors (Pertes and Heir, 1991; Grzesiak, 1991). In contrast, acute pain is temporary in nature, often self-limiting, serves a biologic signal function, has a specific cause, and responds to therapy (Fricton, 1991; Pertes and Heir, 1991). The patient with chronic pain often suffers from depression and anxiety and may develop dependence on medications, health care professionals, and surgical procedures. Dependence on family and friends can result in low self-esteem. Grzesiak (1991) describes 4 psychologic models of symptom formation in chronic pain (psychodynamic, behavioral, cognitive-behavioral, and cognitive-psychological). The author indicates that the psychological factors are so intermingled with biologic factors that a multidisciplinary approach to ad-

dress both areas is essential for effective management of chronic TMD patients.

Differential diagnosis of chronic orofacial pain may be complex. Pertes and Heir (1991) proposed 3 major pain categories. On the basis of history and physical examination, the primary diagnostic pain category and tissue system affected may be identified. These pain categories are described as somatic, neurogenic, and psychogenic. The 6 tissue systems affected include the following: extracranial, intracranial, musculoskeletal, vascular, neurologic, and psychological. A synopsis of chronic oro-facial pain based on these tissue systems is described briefly in the following summary (Pertes and Heir, 1991; Graff-Radford, 1991; Austin and Cubillos, 1991).

Extracranial. This includes dental pain of odontogenic origin and sinusitis. Dental pain must be differentiated from non-dental causes such as sinusitis, myofascial trigger points, vascular headaches, neuropathies, neuritis, atypical odontalgia, and cardiac pain.

Intracranial. Pain secondary to an intracranial neoplasm, aneurysm, hematoma, hemorrhage, or edema. For patients over 40 years of age with any new persistent headache or a change in chronic headache pattern, a referral to a physician is advised even though this is an uncommon cause of orofacial pain.

Musculoskeletal. This is deep somatic pain that may be caused by MPD or internal derangements. Diagnosis is aided by palpation of trigger points. Cervical spine disorders are also included in this group.

Vascular. These disorders include a variety of headaches including migraine, cluster (Horton's cephalgia), and tension headaches. Temporal arteritis (TA) is a vasculitis characterized by inflammation and destruction of the vessel wall which may be caused by cell-mediated immune mechanisms. TA is often associated with headaches and ocular complaints. Average age of onset is 70 years with a 2:1 female predilection.

Neurologic. This pain is caused by a functional abnormality within the nervous system. Trigeminal neuralgia (tic douloureux, Father Giles' disease) involves the trigeminal nerve (usually the mandibular branch) and is categorized as idiopathic or symptomatic. Idiopathic trigeminal neuralgia (TN) is characterized by paroxysmal, unilateral facial pain confined to the distribution of the trigeminal nerve. The pain is initiated by stimulating trigger zones through touch, talking, chewing, or yawning. The pain is described as brief flashes of excruciating pain lasting a few seconds to a few minutes. Spontaneous remissions are possible. If evidence of a structural cause, neurologic deficit, or other cranial nerve involvement exists, then TN is referred to as symptomatic. Treatment is pharmacologic (tegretol, baclofen, or phenytoin) or surgical (Austin and Cubillos, 1991). Other neurologic disorders include glossopharyngeal neuralgia, deafferentation pain syndromes (atypical odontalgia, trauma neuromas, and neuritis), and paroxysmal neuralgia. Hor-

ton's cephalgia (or cluster headache) has also been included in this category (Lazar et al., 1980). These cluster headaches are characterized by unilateral severe pain which begins in the retro-orbital, forehead, and maxillary regions. These begin suddenly and may increase in intensity for 15 to 180 minutes. Males are affected 6 times more than females.

Psychological. Emotional and psychological factors are the primary cause of the pain complaint with no apparent organic basis.

Miscellaneous Problems

Blackwood (1969) described other problems which may mimic TMD. These include degenerative arthritis, rheumatoid arthritis, growth disturbances, disk lesions, and osteoarthritis. A brief summary of the author's descriptions of these conditions follows.

Degenerative arthritis (DA). This condition may affect up to 100% of patients, especially in weight-bearing joints (knee) of 80- to 95-year-olds, with less incidence reported for non-weight bearing joints. DA is seen in the TMJ in approximately 40% of individuals age 40 and older. Degenerative changes are seen in the bone and cartilage. Ankylosis is seldom the result of degenerative arthritis.

Rheumatoid arthritis (RA). RA is rarely observed initially in the TMJ. However, when present, it usually occurs bilaterally. The active disease involves inflammation of synovial tissues with infiltration of plasma cells and lymphocytes resulting in joint deformity. Little repair is observed histologically.

Growth disturbances. These usually manifest as changes associated with secondary hyperparathyroidism, chronic leukemia, and achondroplasia. All impair endochondral bone formation. Local disturbances in growth may also be seen.

Disk lesions. Perforations may be associated with osteoarthritis or attributed to unknown cause. Tears of the posterior attachment will result in a forward displacement of the disk. Histologic changes are mostly degenerative.

Osteoarthrosis. In 1973, Toller described this degenerative disease of unknown etiology. The 130 cases surveyed in his report were derived from 1,573 cases of TMJ lesions and accounted for 8% of the total. Major signs and symptoms include pain on jaw movement which is often more severe later in the day, limitation of movement, crepitus (not clicking), tenderness over the condyle, radiographic changes at first examination, and, less frequently, aching on the side of the face. The majority of patients had intact dentitions with adequate occlusal support. Females were affected 6 times as often as males and age of onset ranged from 20 to 80+ years, peaking in the fourth to fifth decades. Patients diagnosed with osteoarthrosis did not present with signs of arthritis. Only 5% had a relevant history of trauma. Radiographic changes using a transpharyngeal technique revealed either loss of lamina dura or a cupping excavation of the condyle around the point of contact with the articular

eminence. Although radiographic changes were not always evident at the first visit, a diagnosis of osteoarthritis was not confirmed until radiographic changes were observed. As severity of symptoms increased or persisted, radiographic changes usually became more severe. Within 2 to 3 years, radiographs revealed rounding of sharp edges and remineralization of the articular surface which often formed at an oblique angle and was reduced in size. Diagnosis of osteoarthritis should rule out pain dysfunction syndrome, osteoarthritis, and other erosive diseases of bone such as neoplasms. Normally the disease is self-limiting with most cases being symptom-free within 2 years. Treatment is empirical and may include pain alleviation (pain medication, massage, heat), correction of dental deficiencies, and establishment of proper vertical dimension. Crepitus often persists but should not cause concern in a symptom-free patient. While the value and safety of intra-articular steroid injection is questionable, the author recommends a single injection of Prednisolone (25 mg) for relief of acute pain. For cases which do not respond to conservative treatment and in which the patient has intractable pain and lack of function, a condylectomy might be considered. Of 19 cases treated surgically, 13 had excellent results, 3 improved, and 1 was a failure.

SUMMARY

TMD is responsible for most orofacial pain. Characteristic signs include joint noise, muscle tenderness, pain, and limitation of mandibular motion. Common symptoms include facial pain, headache, joint noise, and jaw function difficulties. Multiple factors have a role in TMD including parafunctional habits, stress, trauma, and malocclusion. MPD and disk displacements are the 2 most common TM disorders (Fricton, 1991). MPD is a regional muscle pain disorder characterized by muscle tenderness, slight limitation in range of motion, and local and referred pain. TMJ disk displacements are characterized by progressive stages of clinical dysfunction. Joint alterations usually consist of an anteriorly displaced disk caused by trauma, laxity of the ligaments, and changes in the fluid environment of the joint. Displacement is often associated with TMJ capsulitis, pain, tenderness, and joint swelling. TMD screening should be part of the routine dental examination for all patients but TMJ imaging is indicated only if recent or progressive pathologic joint condition exists based on the clinical examination and history. Imaging is not indicated for joint sounds in the absence of other TMD signs and symptoms. Goals of therapy should include pain reduction, restoration of normal jaw function, and reduction of need for future health care. Treatment should start conservatively and progress as needed.

REFERENCES

- Attanasio R. Nocturnal bruxism and its clinical management. *Dent Clin N Am* 1991;35:245–252.
- Austin D, Cubillos L. Special considerations in orofacial pain. *Dent Clin N Am* 1991;35:227–244.
- Baragona P, Cohen H. Long-term orthopedic appliance therapy. *Dent Clin N Am* 1991;35:109–122.
- Blackwood HJJ. Pathology of the temporomandibular joint. *J Am Dent Assoc* 1969;79:118–124.
- Clark G. A critical evaluation of orthopedic interocclusal appliance therapy: Design, theory and overall effectiveness. *J Am Dent Assoc* 1984;108:364–368.
- Costen JB. A syndrome of ear and sinus symptoms dependent upon disturbed function of the temporomandibular joint. *Ann Otol Rhino Laryngol* 1934;43:1–15.
- DeBoever JA. *Functional Disturbances of the TMJ*. St. Louis: CV Mosby Co.; 1977.
- Dixon DC. Diagnostic imaging of the temporomandibular joint. *Dent Clin N Am* 1991;35:53–74.
- Farrar WB. Differentiation of temporomandibular joint dysfunction to simplify treatment. *J Pros Dent* 1972;28:629–636.
- Fricton J. Recent advances in temporomandibular disorders and orofacial pain. *J Am Dent Assoc* 1991;122:25–32.
- Graff-Radford S. Headache problems that can present as toothache. *Dent Clin N Am* 1991;35:155–170.
- Greene CS, Laskin DM. Long-term evaluation of treatment for myofascial pain-dysfunction syndrome: A comparative analysis. *J Am Dent Assoc* 1983;106:75–77.
- Griffiths RE. Report of the president's conference on the examination, diagnosis and management of temporomandibular disorders. *J Am Dent Assoc* 1983;106:75–77.
- Grzesiak R. Psychologic considerations in temporomandibular dysfunction: A biopsychosocial view of symptom formation. *Dent Clin N Am* 1991;35:209–226.
- Guralnick W, Kaban LB, Merrill RG. Temporomandibular joint afflictions. *New Engl J Med* 1978;299:123–129.
- Hoffman N, Moses J, Topper D. Temporomandibular joint surgery. *Dent Clin N Am* 1991;35:89–107.
- Lazar ML, Greenlee RG, Naarden AL. Facial pain of neurologic origin mimicking oral pathologic conditions: Some current concepts and treatment. *J Am Dent Assoc* 1980;100:884–888.
- Laskin D. Etiology of the pain-dysfunction syndrome. *J Am Dent Assoc* 1969;79:147–153.
- McNeil C, Mohl N, Rugh JD, Tanaka TT. Temporomandibular disorders: Diagnosis, management, education, and research. *J Am Dent Assoc* 1990;120:253–263.
- Okeson JP. Nonsurgical management of disc-interference disorders. *Dent Clin N Am* 1991;35:29–52.
- Pertes R, Heir G. Chronic orofacial pain: A practical approach to differential diagnosis. *Dent Clin N Am* 1991;35:123–140.
- Rees L. The structure and function of the mandibular joint. *Br Dent J* 1954;96:125–133.
- Rugh JD, Solberg WK. Psychological implications in temporomandibular pain and dysfunction. *Oral Sci Rev* 1976;7:3–30.
- Schwartz LL. Pain associated with the temporomandibular joint. *J Am Dent Assoc* 1955;51:393–397.
- Stockstill J, Mohl N. Evaluation of temporomandibular joint sounds: Diagnostic analysis and clinical implications. *Dent Clin N Am* 1991;135:75–88.
- Toller PA. Osteoarthritis of the mandibular condyle. *Br Dent J* 1973;134:223–331.

Section 2. Occlusion: Theory

REVIEW

Weisgold (1969) reviewed the major concepts of occlusion from the 1920s through the 1960s. A summary of his report appears below. Readers are referred to the 1969 article for full references. In the 1920s, Stillman and McCall recognized a relationship between gingival disease and traumatic occlusion, associating excessive force with the presence of gingival clefts or linear depressions (McCall's festoons, Stillman's clefts). Orban (1939) suggested that traumatized tissue may be at an increased risk for inflammation and that inflamed tissue would yield more easily to trauma, but still stressed the existence of 2 separate periodontal lesions. In a rat model, Macapanpan and Weinmann (1954) noted that trauma caused damage to the periodontal ligament (PDL) and that the inflammatory exudate was directed into the PDL. Glickman and Smulow (1957, 1962) believed that presence of inflammation and occlusal trauma could lead to angular bone destruction. Akiyoshi and Mori (1967) evaluated autopsy specimens and suggested that gingival inflammation from the interdental papilla may extend through transeptal fibers and follow the course of the blood vessels into the interdental septum and the PDL, even if there was no evidence of occlusal trauma. In the late 1920s, gnathologic theories were described, with the true hinge axis being proposed by McCollum et al. Intercuspal position in the terminal hinge position was stressed. Schuyler, in the 1930s and 1940s, proposed guidelines of occlusal adjustment, advocating the elimination of balancing side contacts. Youdelis and Mann (1965) also supported elimination of balancing side contacts based on retrospective observations that molar teeth associated with such contacts had greater bone loss, mobility, and pocket depths when compared to molars without balancing contacts.

Posselt (1952) reported that over 90% of subjects had maximum intercuspation anterior and inferior to the retruded position, and that maximum jaw opening required both translatory and rotary movements of the condyle. Jankelson (1953) observed that tooth contact occurs during mastication and swallowing and that centric relation is present during mastication. In the 1960s, Ramfjord advocated occlusal adjustment in centric relation to eliminate bruxism. It was during this same period that Pankey et al. introduced "long centric" as an occlusal relationship.

CENTRIC OCCLUSION VERSUS CENTRIC RELATION

Adams and Zander (1964), using experimental bridges with miniature radio transmitters, questioned the use of centric relation as a desired intercuspation. The authors placed switches at the intercuspation position and lateral to intercuspation. Muscle activity of the temporalis and masseter muscles was also recorded using electromyography. The subjects chewed 3 foods on their left side only, right side

only, and in their usual manner. Chewing sequences were analyzed for the number of chewing strokes, number of tooth contacts for each chewing motion, duration of tooth contact, and relation of tooth contact to muscle activity. All subjects presented tooth contacts lateral to intercuspation with all test foods and all 3 chewing motions. Contact frequency increased for lateral and intercuspation positions as chewing progressed. The longest intercuspation contact occurred during swallowing.

Pameijer et al. (1969) placed a telemetric device in a fixed denture appliance to investigate the occurrence and frequency of single and gliding tooth contacts during chewing, swallowing, and bruxism. The authors reported that most chewing and swallowing occurred in the centric occlusion position, with lateral excursions atypical of the chewing cycle. They also noted that bruxism consisted of repetitive grinding tooth contacts which differed from the haphazard pattern recorded during mastication.

Carwell and McFall (1981) evaluated the incidence and position of tooth contacts using chin point manipulation, bilateral mandibular manipulation, and chin point guidance with an anterior jig. Three groups of 10 patients each were analyzed using 2 of the 3 techniques. Assessments included centric relation contacts, anterior and lateral components of the slide from centric relation to centric occlusion, and non-functional contacts in lateral excursions. The authors also examined the periodontal status and classified the occlusal relationship as Angle's type, cuspid protected, and group function. The chin point jig technique identified the initial point of contact most accurately, but all techniques correctly identified the location of centric relation contacts. Twenty-six (26) of 30 patients had an Angle's Class I occlusion, 14 of 30 had bilateral cuspid-guided occlusion, 8 of 30 had bilateral group function, and 8 of 30 had a combination of cuspid protected and group function relationships. Maxillary and mandibular first premolars were involved with the greatest percentage of centric relation contacts. A slide was present from centric relation to centric occlusion in 90% of patients. Balancing side interferences were present in 21 of 30 patients with first and second molars involved 78% of the time, and second molars only in 56%. Teeth associated with centric relation contacts were not significantly different periodontally from control teeth.

O'Leary et al. (1972) examined tooth mobility in cuspid-protected and group-function occlusions. Mean tooth mobility was higher in the cuspid-protected group for every tooth type.

Ramfjord and Ash (1981) reviewed the role of occlusion relative to the etiology and treatment of periodontitis. The authors indicated that trauma from occlusion (TFO) did not initiate gingivitis or periodontitis, or have a role in disease progression. Active trauma tended to accelerate bone loss and pocket formation depending on the presence of local irritants and inflammation. Hypermobility, without additional signs or symptoms, was not an absolute indication of TFO.

A diagnosis of TFO should be supported by evidence of active injury over time with continued or increasing mobility, persistent discomfort, and radiographic evidence of bone or root resorption. It was noted that a widened PDL was not always indicative of TFO or hypermobility, but may represent physiologic adaptation or past TFO that was self-limiting. Increased mobility with a reduced periodontium did not usually lead to further loss of support. Bruxism could cause primary or secondary TFO, with increased significance depending on level of periodontal support. Marginal ridge discrepancy and plunger cusp's role in the etiology of periodontal disease is not firmly established and neither is the relationship between Angle's malocclusion and periodontal disease. Malocclusion may indirectly affect periodontitis in the presence of poor plaque control, and gingival trauma may result from tissue impingement. Plaque control must be initially established, and occlusal factors addressed subsequently. The authors suggested that long-term splinting was indicated if mobility was found to interfere with the health and comfort of the patient or if the mobility was progressive.

Wasson (1988) described functional occlusion in orthodontic patients and the relationship of the teeth to condylar movements. Changes in occlusion include the angle of incisal guidance, cusp-fossa relationships, and the direction of the occlusal plane. It is suggested that in order to prevent temporomandibular joint disorders, muscular dysfunction, and excessive occlusal wear, the rules of functional occlusion should be followed. The neuromuscular avoidance systems allow the mandible to avoid prematurities during movement. However, this system is absent during sleep, resulting in parafunctional habits which may be detrimental due to the duration of activity of muscles and leverage-producing direction of the applied forces. The most desirable lever in normal jaw function is one which produces work at the end of the lever arm with

a condylar fulcrum, reducing the level of stress. To achieve a sound occlusal result in orthodontic patients, the authors suggest: 1) maximum intercuspation with the mandible in centric relation; 2) immediate anterior disclusion during functional movements; and 3) stable intercuspation allowing opposing cusps to pass without interference.

Burgett et al. (1992) conducted a randomized trial of occlusal adjustment in 50 periodontal patients treated with scaling and root planing or modified Widman flap (MWF) surgery. Following 2 years of quarterly maintenance, mean attachment levels were better in the occlusal adjustment group (significant only in the 4- to 6-mm probing depth) than the unadjusted group, and were better in patients undergoing scaling and root planing than those undergoing modified MWF surgery. Probing depth reduction was greater (not significantly) in patients treated with occlusal adjustments than those not adjusted. Modified Widman flap surgery was more effective at reducing mean probing depths than scaling and root planing.

REFERENCES

- Adams S, Zander H. Functional tooth contacts in lateral and in centric occlusion. *J Am Dent Assoc* 1964;69:465-473.
- Burgett F, Ramfjord S, Nissle R, Morrison E, Charbeneau T, Caffesse R. A randomized trial of occlusal adjustment in the treatment of periodontitis patients. *J Clin Periodontol* 1992;19:381-387.
- Carwell M, McFall W. Centric relation determinations: Clinical and radiographic comparisons. *J Periodontol* 1981;52:347-353.
- O'Leary T, Shanley D, Drake RB. Tooth mobility in cuspid-protected and group-function occlusions. *J Pros Dent* 1972;27:21-25.
- Pameijer J, Glickman I, Roeber FW. Intraoral occlusal telemetry. III. Tooth contacts in chewing, swallowing and bruxism. *J Periodontol* 1969;40:253-258.
- Ramfjord S, Ash M. Significance of occlusion in the etiology and treatment of early, moderate and advanced periodontitis. *J Periodontol* 1981;52:511-517.
- Wasson J. Achieving functional occlusion with orthodontics. *Clin Dent* 1988;2:1-7.